

Kansas Agricultural Experiment Station Research Reports

Volume 0
Issue 1 *Cattleman's Day (1993-2014)*

Article 939

1988

Experimental induction and monitoring of liver abscesses in cattle with ultrasonography

K.F. Lechtenberg

T.B. Avery

Tiruvoor G. Nagaraja

Follow this and additional works at: <https://newprairiepress.org/kaesrr>



Part of the [Other Animal Sciences Commons](#)

Recommended Citation

Lechtenberg, K.F.; Avery, T.B.; and Nagaraja, Tiruvoor G. (1988) "Experimental induction and monitoring of liver abscesses in cattle with ultrasonography," *Kansas Agricultural Experiment Station Research Reports*: Vol. 0: Iss. 1. <https://doi.org/10.4148/2378-5977.2342>

This report is brought to you for free and open access by New Prairie Press. It has been accepted for inclusion in Kansas Agricultural Experiment Station Research Reports by an authorized administrator of New Prairie Press. Copyright 1988 Kansas State University Agricultural Experiment Station and Cooperative Extension Service. Contents of this publication may be freely reproduced for educational purposes. All other rights reserved. Brand names appearing in this publication are for product identification purposes only. No endorsement is intended, nor is criticism implied of similar products not mentioned. K-State Research and Extension is an equal opportunity provider and employer.



Experimental induction and monitoring of liver abscesses in cattle with ultrasonography

Abstract

We have demonstrated that ultrasonography can be used to visualize liver abscess in live cattle. We have also developed a nonsurgical method of catheterizing the bovine portal vein and experimentally inducing liver abscesses by inoculating the portal vein with *Fusobacterium necrophorum* bacteria.

Keywords

Kansas Agricultural Experiment Station contribution; no. 88-363-S; Cattlemen's Day, 1988; Report of progress (Kansas State University. Agricultural Experiment Station and Cooperative Extension Service); 539; Beef; Liver abscess; Ultrasonography

Creative Commons License



This work is licensed under a [Creative Commons Attribution 4.0 License](https://creativecommons.org/licenses/by/4.0/).

K**Experimental Induction and Monitoring of Liver Abscesses in Cattle With Ultrasonography****S****K.F. Lechtenberg, T.G. Nagaraja,
and T.B. Avery¹****U**

Summary

We have demonstrated that ultrasonography can be used to visualize liver abscess in live cattle. We have also developed a nonsurgical method of catheterizing the bovine portal vein and experimentally inducing liver abscesses by inoculating the portal vein with Fusobacterium necrophorum bacteria.

Introduction

Researchers have documented decreased average daily gains and feed efficiency among feedlot cattle with liver abscesses. Losses are likewise incurred by the packers who condemn over three million beef livers annually, the majority because of abscessation. Studies have shown that cattle on high energy rations that do not include antibiotics to control the bacterium, Fusobacterium necrophorum, have abscess incidences of approximately 30%, with different feedlots having ranges from 5-90%.

Experimental Procedure

Six Holstein steers weighing 450 to 650 lbs were used for this study. Animals were placed in a head gate. The right side of the abdomen was clipped and scrubbed. Sterile acoustic jelly was applied on the skin, and the liver was examined with ultrasound equipment to ensure that no liver abscesses were present. A 10 cm square area directly over the portal vein was cleansed with surgical scrubs. Local anesthetic was injected in the 10th rib space over the location of the portal vein. A small incision was made through the skin, and the portal vein was located using ultrasound. A 5 1/4 inch, 14 gauge flexible catheter with stainless steel stylet was guided through the skin incision, muscles, diaphragm, capsule of the liver, liver tissue, and into the portal vein, while observing the procedure with the ultrasound. The steel stylet was removed and sterile flexible tubing was threaded through the larger catheter. An 18-hour broth culture of Fusobacterium necrophorum was injected into the portal circulation via the tubing. The tubing was withdrawn back into the larger catheter and both were removed. No closure of the skin was required. The calves were monitored with the ultrasound equipment daily for 14 days.

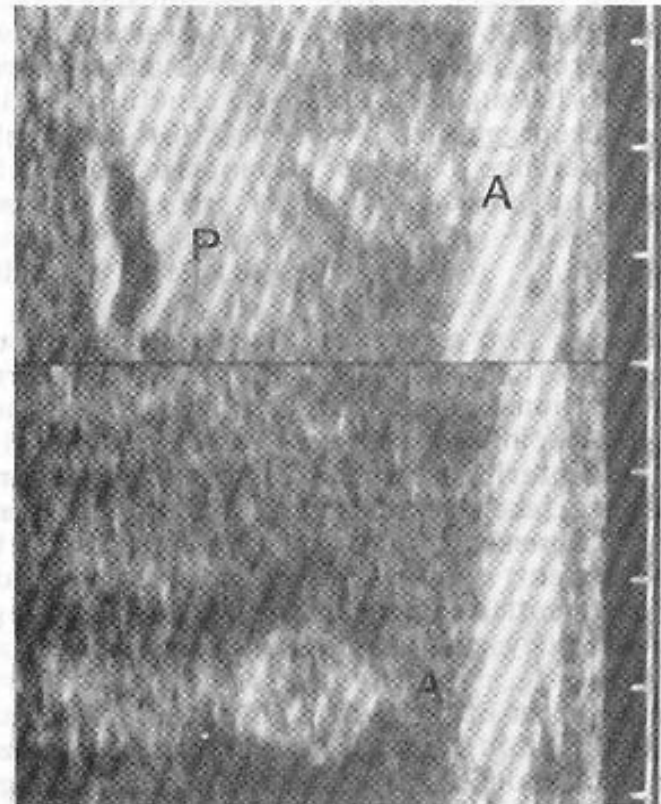
Results and Discussion

Prior to our work, the research and testing of compounds to control liver abscesses took one of two approaches. Experimentally induced liver abscesses were

¹Department of Surgery and Medicine.

the result of tedious and expensive abdominal surgeries, in which the animal was opened up and the portal vein was catheterized and infused. Such an operation obviously stressed the animal. The number of cattle was often limited because of expense and personnel limitations. The other method of liver abscess study, for product evaluation has depended on the incidence of spontaneous abscesses. Cattle were separated into groups and placed on rations containing compounds designed to prevent liver abscesses. The animals were followed to slaughter and incidence of abscesses was determined. The approach is certainly practical, however, it is subject to several unknown variables because there is no certainty that liver abscesses will develop in either treatment or control groups.

All six steers in our study developed multiple liver abscesses. Abscesses were detected by ultrasound within 7 to 8 days in all steers and in some instances as early as 3 days after inoculation of the bacterial culture. The number and location of abscesses were confirmed during postmortem examination of the liver following slaughter. Therefore, ultrasound equipment permits us to visualize the presence of liver abscesses in live cattle. Also, the ability to experimentally induce liver abscesses in cattle provides an ideal experimental model for evaluating new products for prevention of liver abscesses.



On the left, a calf's liver is examined with ultrasonic scanning equipment. The image is sent to both a screen and a camera, producing the image shown on the right. P denotes the portal vein. The circular structures labeled A are liver abscesses.