

Kansas Agricultural Experiment Station Research Reports

Volume 0
Issue 2 *Dairy Research (1984-2014)*

Article 267

2000

Antibiotic versus nonantibiotic products for the treatment of Papillomatous Digital Dermatitis (hairy heel wart) in dairy cattle

J.M. Sargeant

D.P. Gnad

J. Isch

See next page for additional authors

Follow this and additional works at: <https://newprairiepress.org/kaesrr>



Part of the [Dairy Science Commons](#)

Recommended Citation

Sargeant, J.M.; Gnad, D.P.; Isch, J.; and Bathina, H. (2000) "Antibiotic versus nonantibiotic products for the treatment of Papillomatous Digital Dermatitis (hairy heel wart) in dairy cattle," *Kansas Agricultural Experiment Station Research Reports*: Vol. 0: Iss. 2. <https://doi.org/10.4148/2378-5977.3192>

This report is brought to you for free and open access by New Prairie Press. It has been accepted for inclusion in Kansas Agricultural Experiment Station Research Reports by an authorized administrator of New Prairie Press. Copyright 2000 Kansas State University Agricultural Experiment Station and Cooperative Extension Service. Contents of this publication may be freely reproduced for educational purposes. All other rights reserved. Brand names appearing in this publication are for product identification purposes only. No endorsement is intended, nor is criticism implied of similar products not mentioned. K-State Research and Extension is an equal opportunity provider and employer.



Antibiotic versus nonantibiotic products for the treatment of Papillomatous Digital Dermatitis (hairy heel wart) in dairy cattle

Abstract

A field trial was conducted to compare oxytetracycline to three nonantibiotic therapies using bandage protocols for the treatment of hairy heel warts. Affected feet were bandaged for 4 days with either of the four products. Over a 28-day period following bandage removal, heel warts on 44 cows (11 per treatment group) were evaluated based on size, degree of pain, color, and lesion appearance. No differences were detected among treatments, suggesting that nonantibiotic therapies used in bandage protocols may be as effective as oxytetracycline.; Dairy Day, 2000, Kansas State University, Manhattan, KS, 2000;

Keywords

Dairy Day, 2000; Kansas Agricultural Experiment Station contribution; no. 01-166-S; Report of progress (Kansas State University. Agricultural Experiment Station and Cooperative Extension Service); 861; Dairy; Hairy heel warts; Therapy; Nonantibiotic

Creative Commons License



This work is licensed under a [Creative Commons Attribution 4.0 License](https://creativecommons.org/licenses/by/4.0/).

Authors

J.M. Sargeant, D.P. Gnad, J. Isch, and H. Bathina

**ANTIBIOTIC VERSUS NONANTIBIOTIC PRODUCTS FOR THE
TREATMENT OF PAPILLOMATOUS DIGITAL DERMATITIS
(HAIRY HEEL WART) IN DAIRY CATTLE**

*J. M. Sargeant¹, D. P. Gnad², J. E. Shirley,
J. Isch, H. Bathina³, and J. Lising³*

Summary

A field trial was conducted to compare oxytetracycline to three nonantibiotic therapies using bandage protocols for the treatment of hairy heel warts. Affected feet were bandaged for 4 days with either of the four products. Over a 28-day period following bandage removal, heel warts on 44 cows (11 per treatment group) were evaluated based on size, degree of pain, color, and lesion appearance. No differences were detected among treatments, suggesting that nonantibiotic therapies used in bandage protocols may be as effective as oxytetracycline.

(Key Words: Hairy Heel Warts, Therapy, Nonantibiotic.)

Introduction

Papillomatous digital dermatitis (hairy heel wart) is an emerging disease of dairy cattle, which has become an important cause of lameness. A 1996 USDA survey reported that heel warts were detected in cows on 43.5% of U.S. dairies. The presence of hairy heel warts is associated with severe lameness and decreased performance because of pain. The cause of heel warts is not fully understood; however, it is believed to be contagious in nature and likely associated with a spirochete. Many methods have been used to treat hairy heel warts, including footbaths, topical sprays, parenteral antibiotics, and bandages. Oxytetracycline solution in a bandaging protocol seems to offer the best

short-term improvement. However, the potential exists for antibiotic residuals, though none have been reported in clinical trials, and for the development of antibiotic resistance. Therefore, considerable interest exists in developing nonantibiotic products that are efficacious for the treatment of this disease.

The objective of this field trial was to compare antibiotic and nonantibiotic treatment products used in a bandaging protocol for the treatment of papillomatous digital dermatitis.

Procedures

The study was conducted on a 300-head commercial dairy farm in SE Kansas, in an area that averages 37 inches of rain per year and 190 frost-free days. The herd had experienced an increased incidence of hairy heel warts over the previous month. The milking herd was housed in a shaded dry lot with sand-bedded free-stalls and concrete alleys. There were four milking strings, one for 2-year-old cows, and three for older cows based on production. The cows were walked approximately 150 ft on a grooved concrete surface twice daily for milking in a double-13 herringbone milking parlor. Foot baths had not been used for several months and were not used during the course of this study. Premilking heifers and dry cows were housed separately in small groups on dirt drylots with natural shade.

¹Food Animal Health and Management Center.

²Department of Clinical Sciences.

³WestAgro, Inc., Kansas City, Missouri.

All adult milking cows with active hairy heel wart lesions of at least 1 cm in diameter on a single day in March 2000 were enrolled in the trial. All affected cows were evaluated in a standing position for pain and then confined in left lateral recumbency on a tilt table for further lesion evaluation and for the bandaging procedure. They were fitted with leg bands for identification throughout the trial. The lesions were evaluated for size, pain, color, dermatological characteristics, and appearance based on protocols previously developed for the standardized evaluation of hairy heel warts. The evaluation criteria were as follows:

Lesion size. Lesions were measured in two dimensions to the nearest 0.25 inch. Size was recorded as the square area of the lesion.

Pain. Scoring for pain was performed prior to restraining the animals on the tilt table. Pain was evaluated by spraying water on the lesion with a hose spray attachment from a distance of 2 ft. Prior to the actual measurement, both hind feet (or both front feet if the lesion was on a front foot) were sprayed to desensitize the animal to the water application.

0 = no demonstrable pain (does not flinch or raise foot during spraying)

1 = sensitive (flinches and/or raises foot for less than 2 sec)

2 = severe (holds foot off ground for at least 2 sec)

Color.

0 = flesh, indicating a healed lesion

1 = black

2 = gray

3 = white

4 = red

Lesion appearance.

0 = healed

1 = proliferative. Raised lesions with many hair-like skin growths protruding from the surface. Hyperkeratinization of the skin and swelling are associated with mature lesions.

2 = granulomatous. Lesion containing a terry cloth-like texture associated with the intermediate stages of infection.

3 = ulcerative. Flat, red, and raw lesion often involving bleeding, pain, and erythema; usually associated with lesions in the early stages of infection.

Animals were allocated randomly to each of four treatments, using permuted blocks of four to ensure equal numbers per group. Treatments A, B, and C represented different nonantibiotic products, and treatment D was oxytetracycline. The study was conducted in a triple blind manner; neither the herd owner, the person conducting the evaluations, nor the person performing the statistical analysis was aware of the active ingredient in each treatment.

Following cleaning of the lesion with water, treatments were administered by adding 35 ml of each of four treatments to 10 grams of cotton balls. The treatment-soaked cotton was placed against the lesion and bandaged in place using one roll of Vetwrap® and an outer layer of duct tape for waterproofing. The bandages were removed after 4 days.

Follow-up evaluations were performed at the time of bandage removal (day 4) and at days 18 and 32.

The effects of treatments on the overall change in score for size, pain, color, and appearance categories were evaluated using Kruskal-Wallis one-way analysis of variance. The outcome was calculated as the difference between the score on day 1 and at 28 days following bandage removal. Separate analyses were conducted for each category. The effect of treatment on the rate of change in each category over the course of the study was evaluated using repeated measures analysis of variance for each category. Using these two statistical approaches allowed us to test for differences between overall changes in the heel wart lesions among treatments and differences in the rate of change in the heel wart lesions among treatments over time.

Results

The average days in milk of the affected cows was 216 (range: 13 to 415). The group included 25 first-lactation cows, 7 second-lactation cows, 8 third-lactation cows, and 2 fourth-lactation cows. Two animals were culled between week 2 after bandage removal and week 4 after bandage removal for reasons unrelated to the heel wart lesions.

Overall changes. Figure 1 shows the mean percentage changes in lesion size, pain score, color, and lesion appearance between the start and the end of the trial by treatment.

No statistically significant differences were detected in the average changes among treatments.

Changes over time. No significant differences occurred in the rate of change over time for any of the lesion categories (Figures 2 through 5).

The results show that nonantibiotic products can be as effective as oxytetracycline when used in bandage protocols. Further work is needed to develop and market non-antibiotic therapies.

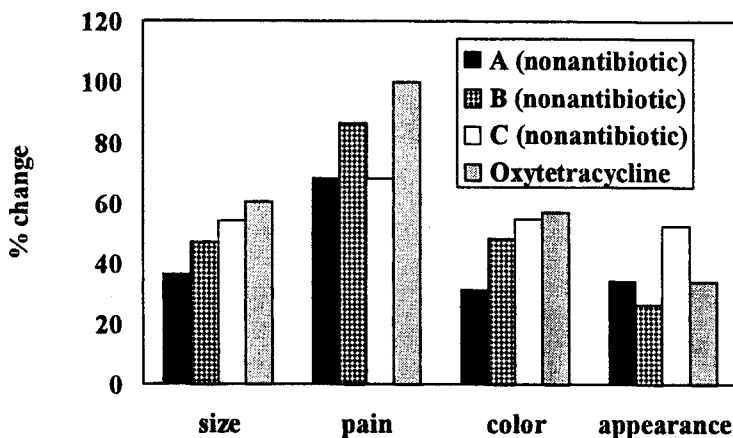


Figure 1. Average Percent Change between Day 1 and Day 32 by Treatment Group.

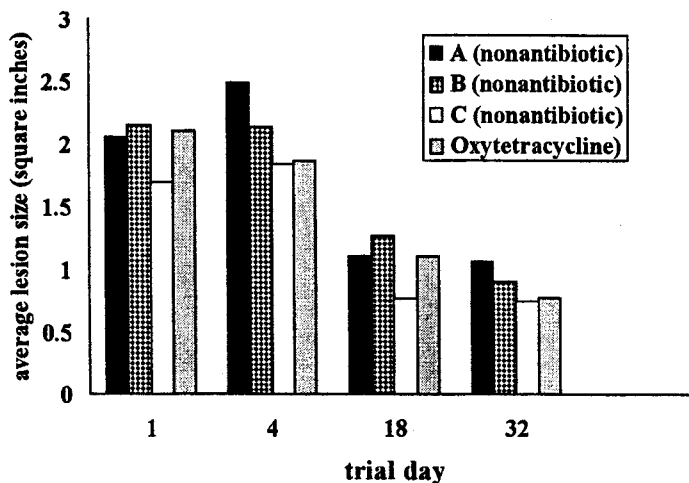


Figure 2. Average Lesion Size over Time by Treatment Group.

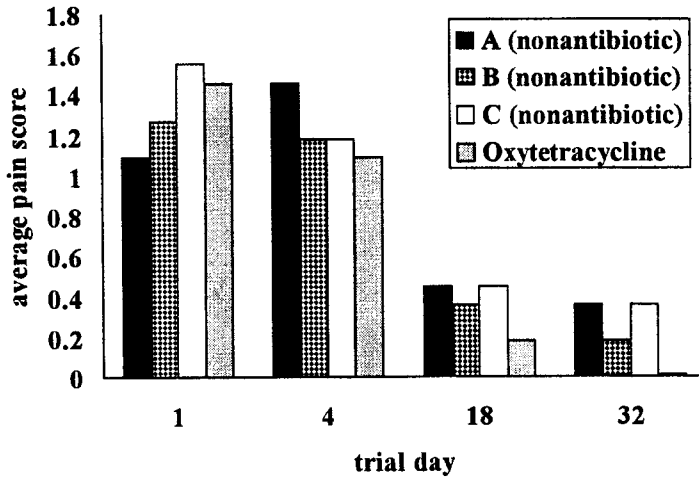


Figure 3. Average Pain Score over Time by Treatment Group.

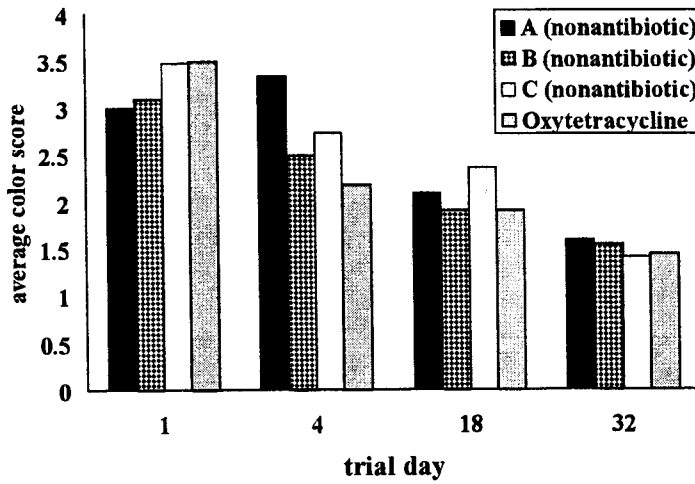


Figure 4. Average Color Score over Time by Treatment Group.

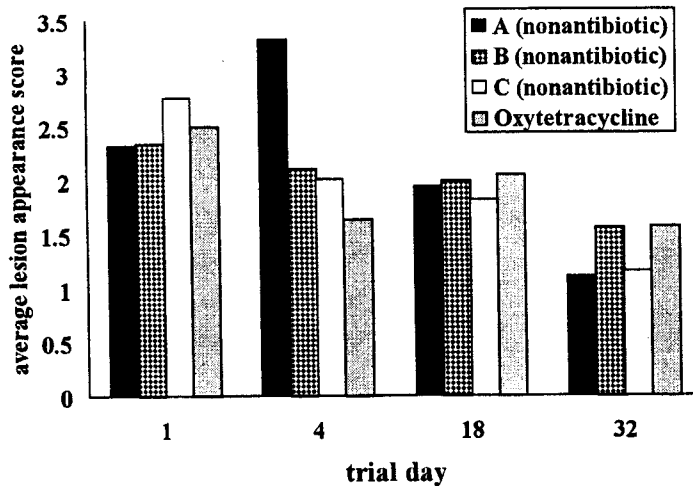


Figure 5. Average Lesion Appearance Score over Time by Treatment Group.