

2005

Porcine reproductive and respiratory syndrome: characteristic features of the infected fetus

Raymond R. Rowland R

Jerome C. Nietfeld

Steven S. Dritz

Follow this and additional works at: <https://newprairiepress.org/kaesrr>

 Part of the [Other Animal Sciences Commons](#)

Recommended Citation

Rowland, Raymond R. R.; Nietfeld, Jerome C.; and Dritz, Steven S. (2005) "Porcine reproductive and respiratory syndrome: characteristic features of the infected fetus," *Kansas Agricultural Experiment Station Research Reports*: Vol. 0: Iss. 10. <https://doi.org/10.4148/2378-5977.6811>

This report is brought to you for free and open access by New Prairie Press. It has been accepted for inclusion in Kansas Agricultural Experiment Station Research Reports by an authorized administrator of New Prairie Press. Copyright 2005 Kansas State University Agricultural Experiment Station and Cooperative Extension Service. Contents of this publication may be freely reproduced for educational purposes. All other rights reserved. Brand names appearing in this publication are for product identification purposes only. No endorsement is intended, nor is criticism implied of similar products not mentioned. K-State Research and Extension is an equal opportunity provider and employer.



Porcine reproductive and respiratory syndrome: characteristic features of the infected fetus

Abstract

Pregnant gilts were infected at 90 days of gestation with porcine reproductive and respiratory virus (PRRSV) isolate SD-23983. Fetuses recovered between 109 and 112 days of gestation were analyzed for the presence of PRRSV. The results showed that not all fetuses were infected, and that infected fetuses tended to be clustered within the uterine horns, suggesting that virus is spread from fetus to fetus. Even though affected litters exhibited different degrees of gross pathology, the presence of an anatomical abnormality was not an identifier of an infected fetus. Analysis of virus replication in individual tissues identified the thymus as the principal site of PRRSV replication. The results show that PRRSV infection in the developing fetus follows a unique course and that PRRSV-induced alterations may be the result of the effect of PRRSV on maternal tissues. These factors need to be taken into consideration when diagnosing PRRSV infection as the cause for aborted and stillborn fetuses.; Swine Day, 2005, Kansas State University, Manhattan, KS, 2005

Keywords

Swine day, 2005; Summary Publication of Report of Progress (Kansas State University. Agricultural Experiment Station and Cooperative Extension Service); 964; Kansas Agricultural Experiment Station contribution; no. 06-63-S; Porcine Reproductive and Respiratory Syndrome Virus; PRRS; Diagnostics; Fetal infection; Swine

Creative Commons License



This work is licensed under a [Creative Commons Attribution 4.0 License](https://creativecommons.org/licenses/by/4.0/).

**PORCINE REPRODUCTIVE AND RESPIRATORY SYNDROME:
CHARACTERISTIC FEATURES OF THE INFECTED FETUS¹**

R.R.R Rowland, J Nietfeld, and S. S. Dritz²

Summary

Pregnant gilts were infected at 90 days of gestation with porcine reproductive and respiratory virus (PRRSV) isolate SD-23983. Fetuses recovered between 109 and 112 days of gestation were analyzed for the presence of PRRSV. The results showed that not all fetuses were infected, and that infected fetuses tended to be clustered within the uterine horns, suggesting that virus is spread from fetus to fetus. Even though affected litters exhibited different degrees of gross pathology, the presence of an anatomical abnormality was not an identifier of an infected fetus. Analysis of virus replication in individual tissues identified the thymus as the principal site of PRRSV replication. The results show that PRRSV infection in the developing fetus follows a unique course and that PRRSV-induced alterations may be the result of the effect of PRRSV on maternal tissues. These factors need to be taken into consideration when diagnosing PRRSV infection as the cause for aborted and stillborn fetuses.

(Key Words: Porcine Reproductive and Respiratory Syndrome Virus, PRRS, Diagnostics, Fetal Infection.)

Introduction

At present, porcine reproductive and respiratory syndrome (PRRS) is responsible for incurring approximately \$600 million a year in losses to producers. The reproductive form of PRRS is initiated by the infection of pregnant gilts/sows at about 90 days of gestation. Outcomes range from aborted and stillborn fetuses to piglets that are born live, but weak, with mortality sometimes approaching 100%. The impact of infection continues through the nursery and finishing stages and contributes to clinical respiratory disease development and mortality. Preventing reproductive PRRS is a key element in the reduction of losses that result from PRRS. The purpose of this study was to characterize sites of virus replication and sources of pathology in the PRRS-affected fetus.

Procedures

All animal procedures were reviewed and approved by the Kansas State University Animal Care and Use Committee. Four pregnant gilts, obtained from a closely monitored PRRSV-negative herd, were infected at 90 days of gestation with a sixth-passage isolate of SDSU-23983, a typical North American field

¹Work supported by USDA-NRI competitive grant No. 03-35205-13704.

²Food Animal Health & Management Center, College of Veterinary Medicine.

isolate. Three milliliters of virus, at a concentration of 10^4 TCID₅₀/ml, was divided into two doses and administered into each nare with a 3-ml syringe or was injected intramuscularly. Two mock-infected gilts served as a sources for normal fetuses. At between 108 and 111 days of gestation, gilts were sacrificed and both uterine horns were removed. Each fetus was individually removed. The location within the uterine horn and gross pathology, if present, were recorded, and fetuses were immediately necropsied. Amniotic fluid and blood were collected first. Tissues for virus isolation (VI) and histopathology included lung, heart, placenta, umbilical cord and the lymphoid-associated tissues, tonsil, thymus, mandibular lymph nodes, and inguinal lymph nodes. Virus isolation was performed by using standard techniques, and results were reported as the log₁₀ of the inverse dilution of the last positive well per 1.0 ml of serum or gram of tissue. The PRRSV-specific antibody was measured in sera by using the HerdCheck® PRRS ELISA (IDEXX). Tissue samples were collected and immediately placed in 10% buffered formalin. Paraffin-embedded thin sections were mounted on slides processed for staining with hematoxylin and eosin (H and E). Immunohistochemical staining for PRRSV nucleocapsid antigen was performed by the diagnostic laboratory.

Results and Discussion

Clinical signs during infection of gilts were minimal. A total of 44 fetuses were recovered from the four infected gilts. Within one to two weeks after challenge, all infected gilts became VI-positive in serum, confirming the presence of an active infection. Three of the four infected gilts seroconverted, as indicated by a PRRSV ELISA S/P ratio greater than 0.39. Gross pathology was observed in all of the infected litters (Figure 1), including poorly developed or dead fetuses, abnormalities in amniotic fluid and placenta. A total of 24 fetuses were obtained from the two control gilts. All control

fetuses seemed normal, except for two mummified fetuses, one less than 5 cm in length. Virus titers in serum and tissues and serology from infected fetuses and dams are presented in Figure 1 and Table 1. Ten of the 42 (24%) viable fetuses were positive for PRRSV by VI in serum. Infection was further confirmed by positive VI and immunohistochemistry (IHC) results from selected tissues. The number of infected fetuses in each litter ranged from no infected fetuses (dam No. 174) to 5 infected fetuses (dam No. 85). Fetuses that were VI-negative in serum were confirmed as PRRSV-negative by negative results for placenta, lung, lymph nodes, and thymus. Seven of the 10 infected fetuses showed some form of gross pathology. Ongoing virus replication in the fetus as the source of these changes is questionable, however, because non-infected fetuses from infected gilts exhibited some form of damage (Figure 1). For instance, the litter from dam No. 174, which was not infected, contained fetuses that were dead or exhibited some form of gross anatomical change. This observation suggests that maternal changes that result from infection are sources of fetal damage.

To identify the targets of virus replication in the fetus, a variety of tissues were assessed for the presence of virus and virus-infected cells. The results are presented in Table 1. Positive VI results were obtained from 6 of 10 lungs, 5 of 10 lymph nodes, 6 of 10 tonsils, and 9 of 10 thymuses. Within this group of tissues, the thymus contained the greatest quantity of virus. For instance, six thymuses yielded virus titers greater than 10^3 /gram. The greatest numbers of antigen-positive slides were also found from thymus (Table 1). Considered together, these data identify the thymus as a primary site of virus replication in the PRRSV-infected fetus.

The results presented in this study describe several unique features of fetal PRRSV infection, which have important implications in the diagnosis of PRRSV as a cause of abortion.

First, not all fetuses are infected. Therefore, when performing VI or PCR to detect virus, several affected fetuses should be collected and/or samples should be pooled from several fetuses. Fetuses should be randomly selected

and should include fetuses that seem “normal”. Tissues chosen for VI or PCR analysis should include thymus. Thoracic fluid, a readily available source of serum and tissue fluid, is also a good source of virus and antibody.

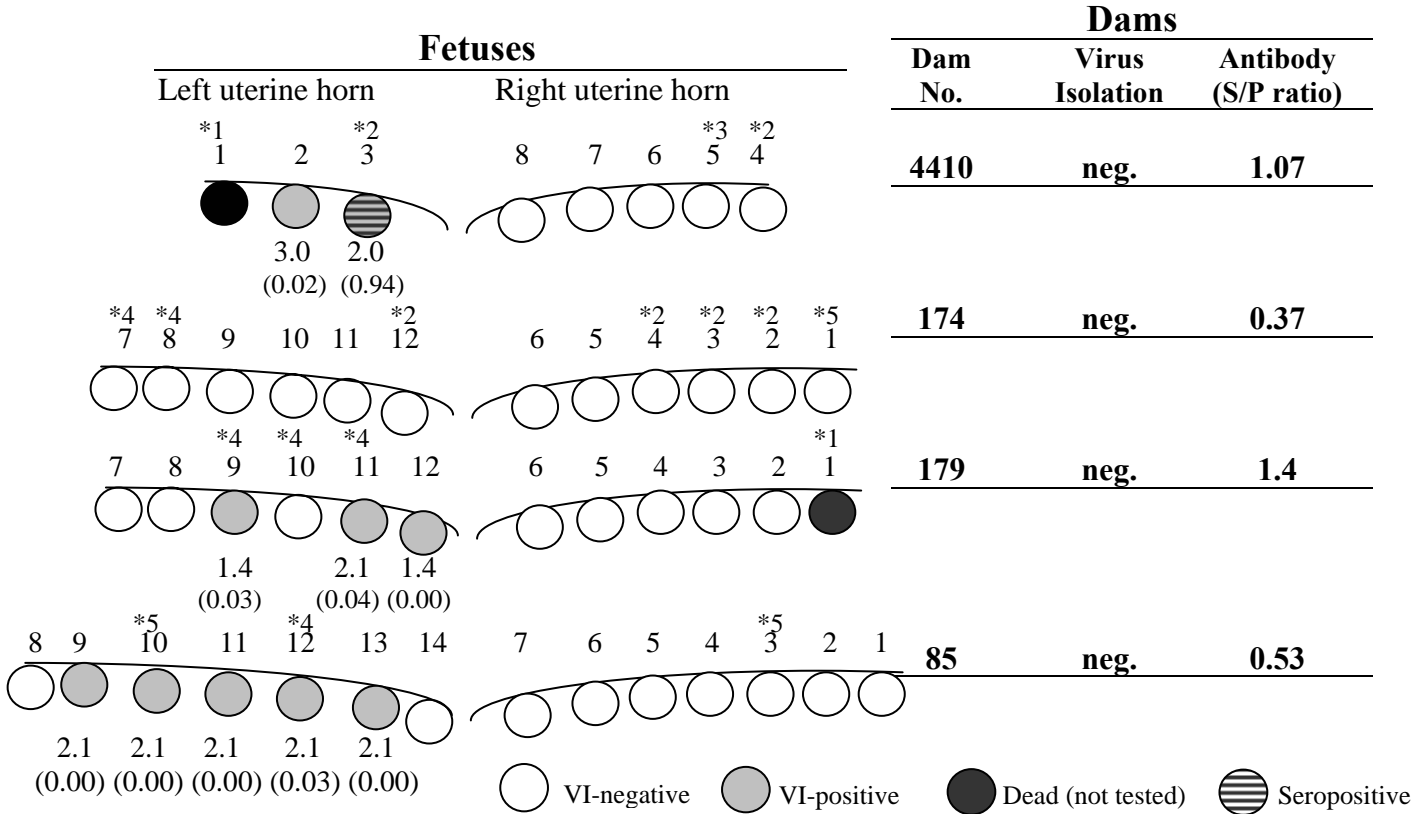


Figure 1. Location of Infected Fetuses Within the Uterine Horns. The identification number, VI, and serology data for each dam are on the right. Each circle represents the relative location of each fetus in the left and right uterine horns. The number above each fetus identifies the order of removal and the number used to identify fetuses in the text and in Table 1. Clear circles represent non-infected fetuses. The VI titer (the number below each shaded fetus), and serology (the numbers in parentheses) were performed on serum. Dead fetuses (black circles) were autolysed and not tested.

Gross Pathology Key

- *1 Partly mummified
- *2 Nonviable fetus or excessively small amounts of amniotic fluid
- *3 Necrotic placenta
- *4 Meconium- and/or blood-stained amniotic fluid
- *5 Small fetus

Table 1. PRRS Virus Isolation and Immunohistochemistry (IHC) in Fetal Tissues¹

Dam No.	4410		179			85				
	2	3	9	11	12	9	10	11	12	13
Placenta	3.6	n.m. ²	1.0	1.6	1.9	2.4	n.m.	n.m.	2.7	1.3
Umbilical cord	n.d. ³	1.4	1.3	2.2	1.6	2.2	2.0	1.2	1.1	1.9
Heart	1.7	1.8	2.5	2.6	1.4	2.8	n.m.	1.3	1.0	2.0
Lung (IHC)	2.1 (-) ⁴	n.m. (-)	1.0 (-)	n.m. (-)	n.m. (-)	0.8 (-)	n.m. (-)	0.7 (-)	0.5 (-)	1.9 (-)
Lymph node ⁵ (IHC)	3.6 (-)	n.m. (-)	2.2 n.d.	2.2 (-)	n.m. n.d.	3.0 (-)	n.m. (-)	n.m. (+)	1.3 (-)	n.m. (+)
Spleen (IHC)	2.3 (-)	n.m. (-)	2.1 (-)	3.1 (-)	2.1 (-)	2.7 (-)	1.9 (-)	1.0 (-)	n.m. (-)	1.6 (+)
Tonsil (IHC)	1.3 (-)	1.4 (-)	1.2 (n.d.)	1.2 (-)	2.2 (-)	3.2 (-)	n.m. (-)	n.m. (-)	n.m. (-)	n.m. (-)
Thymus (IHC)	4.1 (+)	n.m. (-)	1.6 (-)	2.3 (+)	3.6 (+)	1.6 (+)	3.5 (+)	3.5 (+)	2.2 (+)	4.2 (+)

¹The VI results are presented as virus titer per gram of tissue.

²n.m.: Not measured. VI-negative at a dilution of 1:5.

³n.d.: Not determined.

⁴For lung, tonsil, and thymus tissues, the symbol in parenthesis indicates the presence (+) or absence (-) of cells positive for PRRSV antigen. The PRRSV antigen was detected by using immunohistochemistry as described in Figure 2. The results indicate the results obtained for a single thin section.

⁵Virus isolation was performed on mandibular lymph node. Immunohistochemistry data, in parentheses, include results for both mandibular and medial inguinal lymph nodes. A (+) indicates the presence of at least one PRRSV-positive cell.